

# Combination of subcutaneous abdominal wall retraction and optical trocar to minimize pneumoperitoneum-related effects and needle and trocar injuries in laparoscopic surgery

L. Angelini, M. M. Lirici, V. Papaspyropoulos, F. L. Sossi

4th Department of Surgery, Policlinico Umberto I, University La Sapienza, Viale del Policlinico, 155, 00161 Rome, Italy

Received: 11 January 1996/Accepted: 10 February 1997

## Abstract

**Background:** Both pneumoperitoneum and blind needle and trocar insertion may cause complications: because of the well-known physiological effects, CO<sub>2</sub> insufflation is not indicated in patients with impairment of cardiorespiratory function and high-risk patients; injuries to underlying viscera and vessels by needles and trocars have been reported even when the open technique is used.

**Methods:** A technique which combines abdominal wall suspension by a new subcutaneous lifter (LaparoTensor) and optical trocar (OptiView) insertion has been evaluated in a random series of 22 patients undergoing various laparoscopic procedures. The optic trocar was inserted without previous insufflation, but low-pressure (1–5 mmHg) pneumoperitoneum was associated during the course of the procedure in 16 cases.

**Results:** The exposure of the operating field was good or sufficient in 21 cases (95%), while the placement of the optical trocar was always safe. One complication related to the insertion of the subcutaneous needles of the wall lifter occurred (suprafascial hematoma).

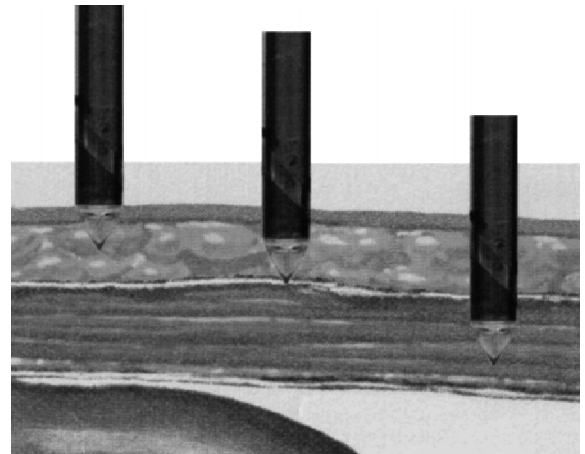
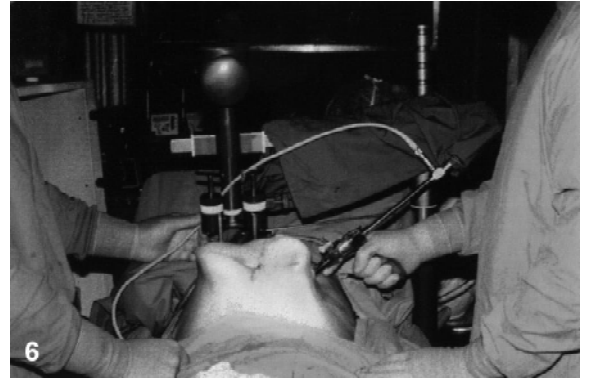
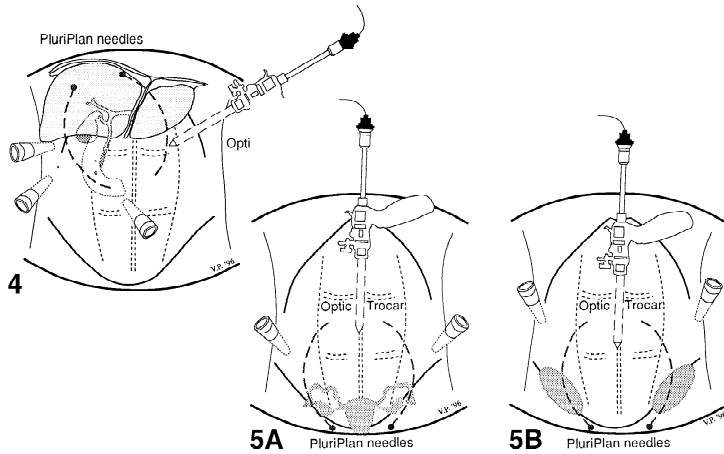

**Conclusions:** The subcutaneous retractor allows the use of conventional cannulae and the combination of abdominal wall suspension with or without low-pressure pneumoperitoneum, thus enhancing the quality of exposure with no effect on the hemodynamic and respiratory functions.

**Key words:** Gasless laparoscopy — Subcutaneous abdominal wall retraction — Optical trocar — Trocar and needle injuries

Both pneumoperitoneum and blind needle and trocar insertion may cause complications. Pathophysiology of gas laparoscopy has been well described (reduction of pulmonary function, splanchnic vasoconstriction, increased physiological dead space, ventilation-perfusion mismatch, increase of total peripheral resistance, increased pulmonary wedge pressure, effects on cardiac output, rise in PaCO<sub>2</sub>) [2]. Whereas in young and healthy people these changes are well tolerated, in patients with impairment of cardiorespiratory functions and in high-risk patients gas-less laparoscopy may be the best option to accomplish surgical procedures by the endoscopic approach. The exposure of the operating field achieved with most abdominal lifting systems is unfortunately poor because of the tenting effect. On the other site, Veress needle and trocars inserted with the conventional blind technique often cause minor or major injuries such as bleeding from the abdominal wall, bleeding from major abdominal vessels, and visceral lesions [1, 3–6, 8]. Injuries may occur even when the open laparoscopy technique is employed [7]. Furthermore, bleeding from the abdominal wall increases the risk of wound infection. The combination of mechanical exposure by a new subcutaneous abdominal wall retractor (LaparoTensor, LT Lucini, Milano, Italy) and endoscopic guided insertion of optical cannulae (OptiView, Ethicon EndoSurgery, Cincinnati, USA) has been employed in a random series of 22 patients undergoing various laparoscopic procedures, with the aim to minimize the risks of needle/trocar injuries and high-pressure pneumoperitoneum.

## Materials and methods

LaparoTensor is a new abdominal lifter provided with specially designed subcutaneous needles (PluriPlan) built according to a mathematical model to distribute forces along all their length for a smooth and balanced suspension (Figs. 1 and 2). The exposure achieved is that of a frustum of a cone. The system is compatible with CO<sub>2</sub> insufflation and does not require special cannulae or open laparoscopy technique. The trocar OptiView is shown in Fig. 3.



**Fig. 1.** LaparoTensor (LT Lucini, Milan, Italy) is an abdominal wall lifter provided with subcutaneous needles which is attached to the operating table and features micro- and macrometric adjustment of the wall suspension.

**Fig. 2.** Special subcutaneous needles (PluriPlan) are designed according to a mathematical model to provide an intraabdominal space with the shape of a frustum of a cone, and deflect if dangerous forces are applied.

**Fig. 3.** OptiView (Ethicon EndoSurgery, Cincinnati, USA) consists of a conventional 10/12-mm disposable cannula and a pistol-grip plastic trocar with a transparent tip, into which the laparoscope is inserted.

**Fig. 4.** Positioning of the access ports and subcutaneous needles for laparoscopic cholecystectomy.

**Fig. 5.** Positioning of the access ports and subcutaneous needles for gynecological procedures (A) and laparoscopic hernia repair (B).

**Fig. 6.** With the abdominal wall lifted up by the LaparoTensor retractor, the OptiView is inserted in the left hypocondrium under visual control with gentle rotating movements and pointing the cannula toward the midline.

**Fig. 7.** The abdominal wall layers are visualized step by step during the insertion of the OptiView: (1) subcutaneous fat, (2) anterior fascia incised, with underlying muscle fibers, (3) last muscle fibers divided and the transparency of the peritoneal leaf.

The technique described here has been employed in 22 cases (12 cholecystectomies, five hysterectomies, one ovariectomy, one TAPP hernia repair [unilateral], one ligation of spermatic vein for left varicocele, one repositioning of inflatable gastric banding, one right colectomy [Table 1]). The position of the subcutaneous suspension needles and that of cannulae is shown in Figs. 4 and 5. In the case of cholecystectomy the points of PluriPlan needle insertion are in the right hypocondrium just below the costal margin. For all procedures in the inferior abdominal cavity, the subcutaneous needles are inserted right above the pubis. The trocar OptiView is inserted in the left hypocondrium for laparoscopic cholecystectomy (Fig. 6) and at the navel site in all other procedures. The quality of exposure achieved during the surgical procedures and the safety of the technique and its advantages and disadvantages have been evaluated.

## Results

Results are shown in Table 1. The exposure of the operating field was good or sufficient in 21 cases (95%). The placement of the optical trocar was always safe. Low-pressure CO<sub>2</sub> insufflation improved exposure and allowed total exploration of the peritoneal cavity in 16 cases (maximum pressure 5 mmHg). Gas insufflation has always started after placement of all operating cannulae.

The exposure of the operating field at the site of the anastomosis during right colectomy was insufficient. In this

**Table 1.** Quality of exposure and ease and safety of trocar insertion<sup>a</sup>

Procedure	Exposure	Trocar insertion
Laparoscopic cholecystectomy		
1. P. S.	Sufficient	Easy and safe
2. A. M. T.	Good + CO <sub>2</sub> insufflation	Easy and safe
3. A. S.	Sufficient	Easy and safe
4. C. P.	Good + CO <sub>2</sub> insufflation	Little problems, safe
5. S. C.	Good + CO <sub>2</sub> insufflation	Little problems, safe
6. A. G.	Sufficient	Easy and safe
7. A. F. M.	Sufficient	Easy and safe
8. C. I.	Good	Little problems, safe
9. M. L.	Sufficient	Easy and safe
10. M. V. P.	Sufficient + CO <sub>2</sub> insufflation	Easy and safe
11. N. F.	Sufficient + CO <sub>2</sub> insufflation	Easy and safe
12. A. O.	Sufficient + CO <sub>2</sub> insufflation	Easy and safe
LAVH & laparoscopic semm hysterectomy		
1. P. T.	Sufficient + CO <sub>2</sub> insufflation	Easy and safe
2. C. P.	Good + CO <sub>2</sub> insufflation	Easy and safe
3. D. M.	Sufficient + CO <sub>2</sub> insufflation	Some resistance, safe
4. A. M. P.	Good + CO <sub>2</sub> insufflation	Some resistance, safe
5. A. F.	Good + CO <sub>2</sub> insufflation	Some resistance, safe
Laparoscopic Ovaryectomy		
1. M. P. P.	Good + CO <sub>2</sub> insufflation	Easy and safe
Laparoscopic TAPP hernia repair		
1. G. T.	Good + CO <sub>2</sub> insufflation	Easy and safe
Laparoscopic ligation of spermatic veins		
1. G. C.	Good + CO <sub>2</sub> insufflation	Some resistance, safe
Laparoscopic gastric banding repositioning		
1. L. M.	Good + CO <sub>2</sub> insufflation	Easy and safe
Laparoscopic right colectomy		
1. A. S.	Insufficient + CO <sub>2</sub> insufflation	Easy and safe

<sup>a</sup> The procedure performed and the initials of the patients are reported in column 1. In 16 cases low-pressure pneumoperitoneum (1–5 mmHg) has been combined with abdominal wall suspension. In cases where little problems were encountered during trocar placement, the access into the peritoneal cavity was initially uncertain.

case (a patient with Crohn's disease) the operation was converted because it wasn't possible to bring the ileum up to the transverse colon because of its extensive posterior attachments.

One complication related to the described technique occurred in the last cholecystectomy: a parietal hematoma of the left flank likely caused by the subcutaneous needle. This operation was converted because of the severe adhesions due to a previous operation on the stomach, and because it was impossible to carry out a safe dissection.

In three cases the access into the peritoneal cavity was uncertain. This occurred in the first patients of this series who underwent laparoscopic cholecystectomies, and was mainly related to the different direction which has to be followed while inserting the trocar with the abdominal wall lifted up: the puncture-cannula must not be pointed downward but toward the midline. Changing the angle of insertion allowed the visualization of the peritoneal cavity in all cases.

## Discussion

The combination of subcutaneous abdominal wall retraction and optical trocars effectively avoids pneumoperitoneum and trocar and needle injuries in laparoscopic surgery.

The latter have been reported by several authors in recent years (Table 2). LaparoTensor may cause some space constraints, hindering some movements of the working instruments. To avoid this, the position of cannulae has to be slightly changed.

**Table 2.** Trocar and needle injuries and reference authors who reported them in the last 5 years

Injury	Reference article
Bleeding abdominal wall	
Veress needle	Fitzgibbons [3] Hulka [4]
Trocar	Fitzgibbons [3] Hurd [5] Soderstrom [8]
Bleeding major vessels	
Veress needle	Fitzgibbons [3] Hulka [4] Hurd [5]
Trocar	Apelgren [1] Fitzgibbons [3] Hurd [5] Soderstrom [8]
Visceral injury	
Veress needle	Fitzgibbons [3] Hulka [4] Reich [6] Soderstrom [8]
Trocar	Reich [6] Soderstrom [8]
Open laparoscopy technique	Sadeghi-Nejad [7]

The best exposure is achieved by gas insufflation with peritoneal pressures up to 15 mmHg. Nevertheless, CO<sub>2</sub> insufflation must be avoided in some patients who may have maximum benefit from abdominal wall suspension.

The LaparoTensor may also be employed with or with-

out gas insufflation, and it has been successfully used during laparoscopic assisted vaginal hysterectomy, allowing endoscopic guidance of the vaginal step of the procedure. The insertion of the optical trocar has been always safe, with precise visual identification of the wall layers (Fig. 7). Because of its limited sharpness, when inserted at the navel site, the trocar OptiView should be pointed slightly at the side of the navel to avoid the midline, which often offers a certain resistance.

## References

1. Apelgren KN, Scheeres DE (1994) Aortic injury. *Surg Endosc* 8: 689–691
2. Baxter JN, O'Dwyer PJ (1995) Pathophysiology of laparoscopy. *Br J Surg* 82: 1–2
3. Fitzgibbons RJ, Annibali R, Litke BS (1993) Gallbladder and gallstone removal: open versus closed laparoscopy, and pneumoperitoneum. *Am J Surg* 165: 497–504
4. Hulka J, Reich H (1994) *Textbook of laparoscopy*. WB Saunders, Philadelphia, PA, pp 339–345, 353–359
5. Hurd WW, Pearl ML, DeLancey JOL, Quint EH, Garnett B, Bude RO (1993) Laparoscopic injury of abdominal wall vessels: a report of three cases. *Obstet Gynecol* 82(4): 2
6. Reich H (1992) Laparoscopic bowel injury. *Surg Laparosc Endosc* 2(1): 74–78
7. Sadeghi-Nejad H, Kavoussi L, Peters C (1994) Bowel injury in open technique laparoscopic cannula placement. *Urology* 43(4): 559–560
8. Soderstrom RM, Levinson C, Levy B (1993) Complications of operative laparoscopy. In: Soderstrom RM (ed) *Operative laparoscopy: the Masters technique*. Raven Press, New York